Paediatric Pearls

August 2015

Put together by: Dr Julia Thomson, Consultant Paediatrician, julia.thomson@bartshealth.nhs.uk

Previous editions are all available at www.paediatricpearls.co.uk

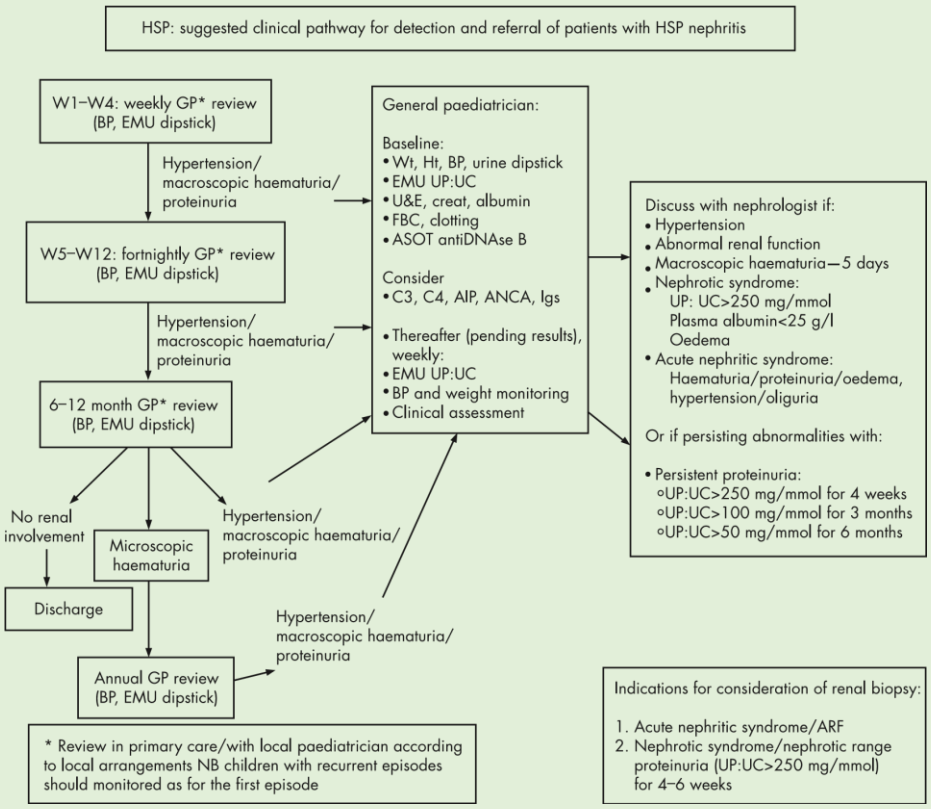

Reference:
E J Tizard and M J J Hamilton-Ayres Henoch–Schönlein purpura Arch Dis Child Educ Pract Ed 2008 93: 1-8

Henoch Schönlein purpura (HSP)

- a disease involving inflammation of small blood vessels
- cause unknown but probably an abnormal immune response to a viral or bacterial infection
- most commonly occurs in children aged 2-11 (M>F)
- if adults get it, disease is usually more severe than in children
- inflammation ➡ leaky blood vessels in the skin, intestines, kidneys (and rarely in heart, lungs and brain). The main symptom is a purpuric rash classically over the legs or buttocks.
- patients also get joint pain (in 75% of cases and usually only lasts a few days), abdominal pain (risk of intussusception (2-3% incidence)) and haematuria (**50% get nephritis which needs monitoring** as 5% go on to get progressive kidney disease).
- lasts 4-6 weeks - sometimes with recurrence of symptoms (about one third), but usually with no long-term consequences
- if kidneys and/or intestines are affected, treatment with steroids may be (rarely) needed
- paracetamol and ibuprofen are appropriate for management of joint pain
- see algorithm for follow up recommendations:
  - no proteinuria? for blood pressure checking and urinalysis at days 7 and 14 and at 1, 3, 6 and 12 months
  - with proteinuria, follow-up should be at days 7 and 14, monthly from 1-6 months and then at 12 months

more information at http://patient.info/doctor/henoch-schonlein-purpura-pro

good parent information leaflet: http://kidshealth.org/parent/medical/heart/hsp.html

Dr Locke's dermatology slot: Think "PVL" in young, healthy people with recurrent and painful spots/red areas on the skin (boils, folliculitis, carbuncles, cellulitis), often at multiple sites which can persist despite appropriate antibiotic treatment. The affected area is often more painful than the size of the lesion would suggest.

- Panton-Valentine Leukocidin (PVL) is a toxin produced by some strains of *Staphylococcus aureus* (PVL-SA)
- PVL can be produced by MSSA (methicillin sensitive) and MRSA (methicillin resistant)
- PVL-SA usually causes pyogenic skin infections e.g. boils and abscesses, but can also cause invasive disease such as osteomyelitis, and should be suspected with:
  - recurrent boils, folliculitis or cellulitis
  - clustering of skin infections within a household or social group
  - necrotic skin infections

PVL-SA infections spread more easily among close contact communities, such as families, nurseries and care homes, but also can be identified in gym groups or those playing close contact sports

Clear summary of clinical features, investigations, and treatment at https://www.gov.uk/government/uploads/system/uploads/attachment_data/file/391168/PVL_guidance_in_primary_care_quick_reference_guide.pdf

British Association of Dermatologists patient information leaflet: http://www.bad.org.uk/shared/get-file.ashx?id=179&itemtype=document

Public Health England advice on how to use the decolonisation treatments: http://www.iph.cam.ac.uk/files/2014/03/C20-PVL-SA-decolonisation-factsheet-Jun-2013.pdf

Reference (Royal College of Nursing, a more informative document): https://www.rcn.org.uk/ data/assets/pdf_file/0008/400787/004128.pdf

Pictures? See the PCDS article on folliculitis and boils: http://www.pcds.org.uk/clinical-guidance/folliculitis-an-overview

ENT with Mr Sunil Sharma

Paediatric acute Mastoiditis

Picture taken from http://emedicine.medscape.com/article/966099-clinical#b2

Mastoiditis = acute inflammation of mastoid air cells (fairly common)
However, clinical presentation of **acute** mastoiditis (**ENT emergency**) is when there is pus in the mastoid cavity secondary to an acute otitis media
Acute mastoiditis less common now with the advent of antibiotic treatment for otitis media (AOM). Usually occurs in children <2yrs of age due to immature immune system

Most common bacterial causes: Strep. pneumoniae, followed by Haemophilus influenzae and Strep. pyogenes

Signs and symptoms:
* Recent AOM
* Fever
* Unilateral otalgia
* Hearing loss
* Non-specific symptoms (poor feeding, irritability)
* Bulging erythematous tympanic membrane
* Tender, erythematous, swollen post auricular region, leading to protusion of auricle
* Loss of postauricular skin crease (see picture)
* Sagging of posterior superior canal wall

Management: Refer urgently to ENT (some can be managed medically with IV antibiotics but some will need incision and drainage of abscess + cortical mastoidectomy and grommet insertion). If untreated, can lead to facial nerve palsy, , Bezold abscess (a deep abscess in the soft tissues of the neck), labyrinthitis, petrositis leading to Gradenigo syndrome (triad of abducens nerve palsy, deep facial pain from trigeminal nerve involvement, and suppurative otitis media), intracranial complications.

Excellent review paper on the topic - Glynn F, Osman L, Colreavy M, Rowley H, Dwyer TP, Blayney A. Acute mastoiditis in children: presentation and long term consequences. J Laryngol Otol 2008 **122**(3):233-7.

Bronchiolitis in children. NICE guidelines [NG9]
Published date: June 2015

The bronchiolitis season will soon be upon us again here in the UK. I have summarised *Assessment and diagnosis*, W*hen to refer/admit* here. Part 2 of this topic on *Management* and *Discharge* next month.

Assessment and diagnosis

- occurs in children < 2 years of age, most commonly < 1 year, peaking around 3 - 6 months
- symptoms usually peak day 3-5: 1-3 day coryzal prodrome, persistent cough (resolves in 90% by 3 weeks), respiratory distress, wheeze and/or crackles on auscultation
- only 30% have a fever and it is usually < 39°C (consider a diagnosis of pneumonia if the fever is high or there are persistently focal crackles
- viral induced wheeze is a differential in older infants (multiple recurrent episodes? Family history of atopy?). Asthma is not normally diagnosed in infants.
- poor feeding (typically after 3 to 5 days of illness).
- Babies < 6 weeks of age may present with apnoea without other clinical signs

When to refer (1° care) / admit (2° care):

Immediately if apnoea, child looks seriously unwell, severe respiratory distress (RR > 70bpm, grunting, severe recession, cyanosed), persistent O_2 saturations < 92% in air (measure if correct paediatric equipment and training available)

Consider referral/admission if:
- respiratory rate (RR) > 60 breaths/minute
- inadequate oral fluid intake (50–75% of usual volume) +/- clinical dehydration
- take following risk factors for severe bronchiolitis into account: chronic lung disease, congenital heart disease, age < 3 months), premature birth < 32/40, neuromuscular disorders, immunodeficiency
- consider other factors: social circumstances, skill and confidence of the carer, distance to healthcare in case of deterioration

Last month I mentioned some services for families struggling with addiction and substance abuse. Lifeline Waltham Forest is a free, safe and confidential drug and alcohol service for any adult over the age of 18 using any kind of drug or alcohol and living in the London Borough of Waltham Forest. Parenting support offered. URL: www.lifelinewalthamforest.org.uk or click here for flyer.