

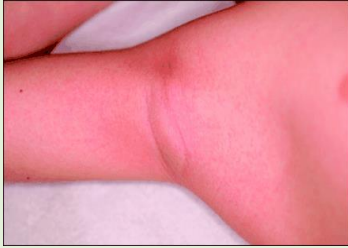# Paediatric Pearls

July 2019

Put together by: Dr Julia Thomson, Consultant Paediatrician, [julia.thomson1@nhs.net](mailto:julia.thomson1@nhs.net)

Previous editions are all available at [www.paediatricpearls.co.uk](http://www.paediatricpearls.co.uk)

## What's in an armpit?

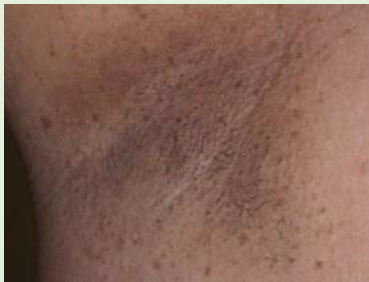

A: 3-year-old child with a fever, sore throat and red tongue.

1. What is the name of this clinical finding?
2. What is the diagnosis?

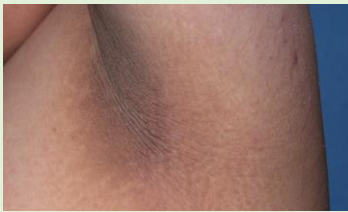B: 12-year-old girl with headaches found, on examination, to have axillary freckling and multiple café au lait patches.

What are 2 possible diagnoses?



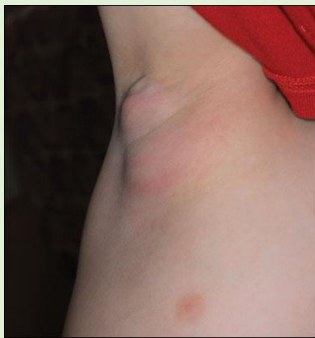C: 11-year-old boy with BMI >99<sup>th</sup> centile who won't go swimming because of his armpit discoloration.

What is the diagnosis and the significance?



D: Right axilla of a 5-year-old immunocompetent boy, treated with antibiotics 2 weeks ago for an infected looking scratch from his kitten on his right hand.

1. What is it?
2. How do you treat it?



### Answers:

A: Pastia lines are bright red lines in the axillary and groin creases seen most notably in Scarlet Fever, caused by streptococcus. Always inspect the underarms of a feverish child. <https://medlineplus.gov/ency/imagepages/19082.htm>

B: Neurofibromatosis I and tuberous sclerosis present with these neurocutaneous markers. They are both autosomal dominant but many are de novo mutations so there is not always a family history. Patient information at [https://www.rch.org.au/kidsinfo/fact\\_sheets/Neurofibromatosis/](https://www.rch.org.au/kidsinfo/fact_sheets/Neurofibromatosis/). Headaches are common in NF1; always do a full examination of a child presenting with headache – including a neurological examination.

C: Acanthosis nigricans signals hyperinsulinism and is a marker for type 2 diabetes. Look for it in obese children as it counts as a significant co-morbidity when looking to refer to a tertiary obesity clinic. Parent information at <https://kidshealth.org/en/parents/acanthosis.html>.

D: Cat Scratch Disease caused by *Bartonella henselae*, gram negative bacillus transmitted particularly by kittens with fleas. Self-resolving usually or prescribe azithromycin if systemically unwell. More info at <https://familydoctor.org/condition/cat-scratch-disease/>. Case from [healio.com](http://healio.com).

### CHILDREN'S SAFEGUARDING SLOT: Harmful Sexual Behaviour (HSB), <https://learning.nspcc.org.uk/health-safeguarding-child-protection/>

HSB has been identified by NHS England as a priority area in health care. NSPCC has created evidence-based resources helping us to recognise and respond to HSB. [Click here](#) for a guide to some relevant Youtube videos for your CPD.

Dr Neaha Patel is looking at "coca-cola coloured urine" over the next few months. See [last month's](#) newsletter for the clinical case which prompted this series.



When is "blood" not haematuria?

HAEMOGLOBINURIA	Intravascular Haemolysis
MYOGLOBINURIA	Rhabdomyolysis

**Haemoglobinuria:** Presence of haemoglobin in the urine, due to intravascular haemolysis. Results in a positive blood test on urine dipstick but no or only a few RBCs on microscopy.

**Myoglobinuria:** Presence of myoglobin in the urine, resulting from muscle breakdown or rhabdomyolysis. Myoglobin is found in muscle cells as a reserve of oxygen. Dipstick and microscopy will show similar results to haemoglobinuria. **Which way to go in this case?**

Our patient had recently been diagnosed with G6PD deficiency and initially we thought she might be haemolysing if she had had an unsuitable antimalarial (eg. primaquine) 2 weeks earlier. But she is a girl. Homozygous females are extremely rare. Heterozygous females can be affected because of a genetic process known as unfavourable X-inactivation. They do then respond to triggers similarly to males (<https://rarediseases.org/rare-diseases/glucose-6-phosphate-dehydrogenase-deficiency/>). We weren't convinced. Other possible causes of haemoglobinuria in this case: malaria, post-artemisinin therapy. More on this next month....

I'm sure I am not the only practitioner who has requested an **Anti-Nuclear Antibody (ANA) test** and then wondered what to do with a result of "1:40 titre, speckled".

The ANA test looks for antibodies to proteins found in the cell nucleus. It is a non-specific screening test for autoimmune diseases (eg rheumatic diseases like SLE and also non-rheumatic diseases like autoimmune hepatitis.) The following quote comes from an excellent internet resource, <https://rheuminfo.com/common-tests/anti-nuclear-antibody-ana-test/>:

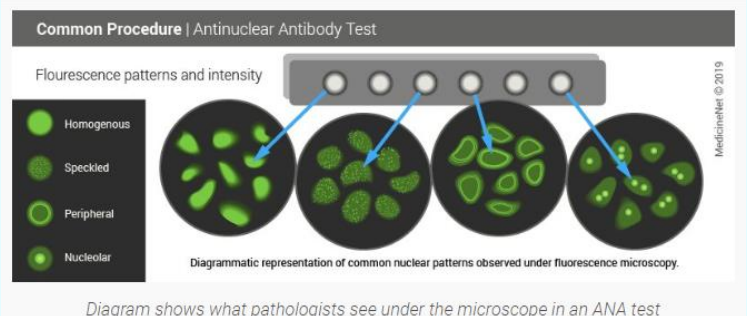
**"The ANA test is like using a fish finder. A fish finder indicates if there are any fish below the surface of the water and gives an idea of how many are there. But it does not say anything about the type of fish or what the fish are doing. The same is true for the ANA test. A positive ANA test confirms that there are antibodies against nuclear proteins, but it does not identify which proteins are under attack."**

The result comes in 2 parts, the titre and the pattern.

**TITRE:** this gives an estimate of how many anti-nuclear antibodies are present. 1 part of the serum is diluted into 40 parts of diluent as the initial screen. If positive (like my patient's result), a new sample is made at half strength (1:80) and, if positive, diluted again to 1:160 and so on until it gets to 1:2560. If the test is positive at this level, the body must have mounted a substantial immune response against nuclear proteins. If the ANA titre is negative or low (1:40, 1:80, even 1:160), there is not usually any autoimmune disease. Pregnancy, old age, viral infections and other inflammatory conditions are causes of false positives. 5% of the normal population have a titre  $\leq$  1:80 all the time. If 1:640 or higher, other more specific tests should be ordered to try and determine what type of nuclear protein is being attacked by the body's own immune system. The height of the titre does correlate with the severity of disease. 99% of people with SLE have a high ANA.

**PATTERN:** the pattern can be homogenous (the least worrying), speckled, nucleolar, centromere or rim enhancing. The ANA pattern refers to the distribution of staining produced by autoantibodies reacting with antigens in the HEp-2 cell nucleus and cytoplasm. Nucleolar pattern is seen in scleroderma, speckled is non-specific and often appears in people with no autoimmune diseases. Unfortunately, the patterns reported, and their significance varies with laboratories.

If my patient's symptoms persist, I might repeat the ANA in a year or so. If she gets better in that time, I am happy that this result is not indicative of an evolving autoimmune disorder like SLE.



Picture above from:

[https://www.medicinenet.com/antinuclear\\_antibody/article.htm#what\\_are\\_antinuclear\\_antibodies](https://www.medicinenet.com/antinuclear_antibody/article.htm#what_are_antinuclear_antibodies)